

Eosinophilic Gastroenteritis and Colitis with Elevated Level of Serum IgA: A Case Report

Fateme Barazandeh Ahmadabadi ¹, Mohammad Ghorbani ², Hamid Reza Niazkar ^{3,*}, Farhad Homapour ⁴, Hedie Nazarzade ⁵, Alireza Rezaei ⁶, Jalil Moshari ⁷

¹ Gastroenterology subspecialist, Department of Internal Medicine, Allame Bohlool Hospital, Gonabad University of Medical Sciences, Gonabad, Iran

² MSc of Hematology and Blood Banking, Faculty member of Gonabad University of Medical Sciences, Gonabad, Iran

³ Medical Student, Student Research Committee, Gonabad University of Medical Sciences, Gonabad, Iran

⁴ Department of Medicine, Faculty of General Surgery, Gonabad University of Medical Sciences, Gonabad, Iran

⁵ Pathologist, Laboratory Technical Assistant, Research Center for Iranian Academic Center for Education, Culture, and Research (ACECR), Khorasan Razavi Branch, Mashhad, Iran

⁶ Clinical Anatomy Pathologist, Assistant Professor, Islamic Azad University of Medical Science, Mashhad, IR Iran

⁷ Department of Pediatrics, School of Medicine, Gonabad University of Medical Sciences, Gonabad, Iran

ABSTRACT

Eosinophilic gastroenteritis is a rare disease with unknown etiology. It is characterized by the eosinophilic infiltration of one or more layers of the gastrointestinal tract. Recently, the authors visited a rare case of eosinophilic gastroenteritis. A 30-year-old woman was admitted to our hospital complaining of acute-onset excessive abdominal pain in the periumbilical region and chronic diarrhea. Physical examination revealed a distended abdomen with tenderness. Complete blood count showed moderate eosinophilia with elevated IgA serum levels. Computed tomography of the abdomen and pelvis was normal. Upper endoscopy (with taking biopsy samples from the stomach and duodenum) and total colonoscopy (with taking biopsy sample from the rectum and ascending colon) were performed. The pathological examination showed a non-destructive colitis with increased mucosal eosinophilia throughout the entire thickness of the ascending colon and duodenum. Rectal and gastric biopsy samples did not show any signs of eosinophilic infiltration. After ruling out of other causes of eosinophilia, eosinophilic gastroenteritis was diagnosed. The patient recovered well after treatment with prednisone (40 mg/day) over two weeks and was free from gastrointestinal symptoms at the time we reported her disease.

Keywords: Gastroenteritis, Eosinophilic Gastroenteritis, Colitis, IgA

please cite this paper as:

Barazandeh Ahmadabadi F, Ghorbani M, Niazkar HR, Homapour F, Nazarzade H, Rezaei AR, Moshari J. Eosinophilic Gastroenteritis and Colitis with Elevated Level of Serum IgA: A Case Report. *Govaresh* 2019;24:179-183.

*Corresponding author:

Hamid Reza Niazkar, MD
Gonabad University of Medical Sciences, Gonabad,
Khorasan Razavi, Iran
Telefax: + 98 51 57223513
Email: hrm185@hotmail.com

Received: 15 Apr. 2019

Edited: 05 Sep. 2019

Accepted: 06 Sep. 2019

INTRODUCTION

Eosinophilic gastroenteritis is a rare digestive disease of unknown etiology described by Kaijser for the first time in 1937(1). It is characterized by the eosinophilic infiltration of one or more layers of the gastrointestinal tract (2), which can occur in children and adults of any age (3). Since the pathogenesis and etiology of the disease are not well understood, no standard criteria exist for the diagnosis of gastroenteritis (4). Talley NJ identified three main diagnostic criteria for eosinophilic gastroenteritis including 1) the presence of gastrointestinal symptoms varying from dyspepsia, ascites, and obstruction to diarrhea depending on the site of involvement, 2)

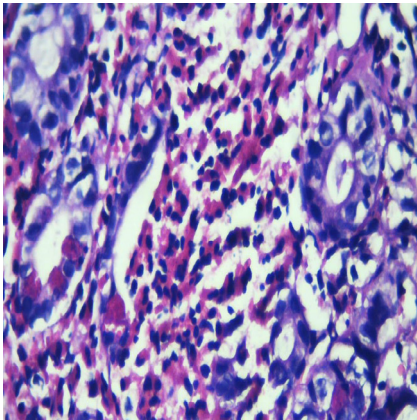


Fig.1: H&E staining, Pathological eosinophil infiltration through ascending colon

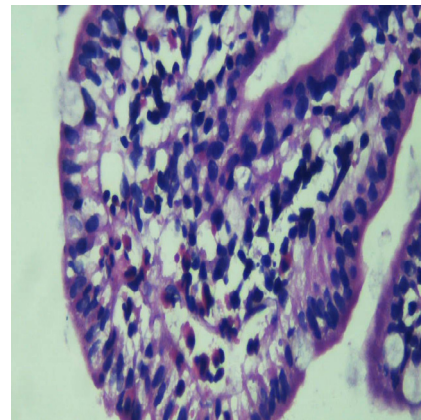


Fig.2: H&E staining, Eosinophil infiltration through duodenum

pathological infiltration of eosinophils in the segments of the gastrointestinal tract, and 3) the exclusion of other diseases with peripheral eosinophilia (5). Eosinophilic infiltration involves variable depths of the gastrointestinal tract, which makes it difficult to be diagnosed and its diagnosis requires a high degree of clinical suspicion and even endoscopic biopsy sampling can miss the diagnosis (6). We present a rare case of eosinophilic gastroenteritis accompanied by peripheral eosinophilia with eosinophilic infiltration throughout the entire thickness of ascending colon and duodenum accompanying lymphocytic colitis and raised IgA serum level.

CASE REPORT

A 30-year-old woman was admitted to our hospital complaining of acute-onset excessive abdominal pain in the umbilical and hypogastric region and chronic diarrhea. The pain was relieved with morphine injections. She had a history of cholecystectomy 3 years earlier. The patient denied taking any drugs or herbal medicine. She had no history of drug allergy, asthma, or allergic rhinitis. Physical examination revealed a distended abdomen with tenderness. Laboratory investigation showed a white blood cell count of $9500/\text{mm}^3$ with 28.1% eosinophilia (absolute eosinophil count of $2660/\text{mm}^3$) with elevated IgA serum level. The patient's stool was checked for ova, parasites, and larva repeatedly but no findings were explaining peripheral eosinophilia. The skin prick test and anti-Echinococcus antibodies (immunoglobulin G)

were also negative. Other laboratory studies such as IgE serum levels were within normal limits. Also, since the signs and symptoms were acute-onset (less than six months), the criteria of the hypereosinophilic syndrome were not fulfilled. Abdominal ultrasonography was normal. The contrast-enhanced computed tomography of the abdomen and pelvis showed lymphadenopathy of the mesenteric and the para-aorta. Other organs including liver, spleen, pancreas, and kidneys were normal. Nested reverse transcriptase-polymerase chain reaction (RT-PCR) examination for the detection of FIP1L1-PDGFR α fusion gene on peripheral blood revealed no product for this fusion gene in the presence of amplified internal control of GAPDH gene and we did not observe any findings in favor of eosinophilia related hematological malignancies.

An upper endoscopy was performed. Endoscopy showed snake skin appearance in the body and fundus of stomach and biopsy samples were taken from the body. Pathological examination was consistent with chronic active gastritis with positive helicobacter pylori bacilli. In a total colonoscopy, rectum had mucosal nodularity while other part of the colon was normal. Biopsy samples were taken from the rectum and normal mucosa of the ascending colon. Pathological examination showed non-destructive colitis with increased mucosal eosinophils in ascending colon (figure 1). Because of continuous abdominal pain, upper endoscopy was repeated. In the latter endoscopy, duodenum had a few erythematous patches.

Table 1: The differential diagnosis of eosinophilic gastroenteritis

Differential Diagnosis of eosinophilic gastroenteritis
Allergic disease: Food allergies, hypereosinophilic syndrome
Gastrointestinal disease: Appendicitis, celiac disease, hypertrophic pyloric stenosis, inflammatory bowel disease
Immunologic disease: Chronic granulomatous disease
Rheumatologic diseases: Connective tissue disease, systemic lupus erythematosus, scleroderma, dermatomyositis, polymyositis, polyarteritis nodosa
Other: Churg-Straus syndrome, inflammatory fibroid polyp, malignancy (carcinomas, lymphomas)
Infection diseases: Ancylostoma caninum (hook worm), Anisakis, ascariis, Epstein-Barr virus, Enterobius vermicularis (pinworm), Eustoma rotundatum, Giardia lamblia, Fasciolopsis, helicobacter pylori, schistosomiasis, Strongyloides Stercoralis, Toxocara canis, Trichinella spiralis
Medication: Azathioprine, Carbamazepine, Clofazimine, Enalapril, Gemfibrozil, Gold salts, Selenium, and vitamin E deficiency

Histologically, we found the increased mucosal eosinophils in the duodenum (figure 2).

After ruling out other causes of eosinophilia, eosinophilic gastroenteritis with the involvement of duodenum and ascending colon was diagnosed. The patient recovered well after the prednisone (40 mg/day) treatment over two weeks. During the follow-up period for 8 months, the patient was completely free of recurrence and was free from gastrointestinal symptoms at the time when we reported her disease.

DISCUSSION

In normal physiological states, eosinophils are seen in the entire gastrointestinal tract except in the esophagus (7). They are responsible for the mucosal immune system of the gastrointestinal tract. They play a role in host defense for healthy individuals (8). The number of eosinophils considered normal in the gastrointestinal tract varies by anatomic site and the highest concentrations are found in the cecum and appendix (9,10). There is no established consensus on a diagnostic threshold regarding the eosinophil count for eosinophilic gastroenteritis (11). The diagnostic threshold number of gastric eosinophils required in eosinophilic gastroenteritis varies among investigators, ranging from 20 eosinophils in one HPF to 30 eosinophils per HPF in at least five HPFs (11). The distinction between normal and pathologically increased eosinophil infiltration outside of the esophagus can be difficult. This has complicated attempts to define standard histological criteria for EGE (Eosinophilic Gastroenteritis).

Eosinophilic gastroenteritis presents with non-specific gastrointestinal symptoms and can involve each and every parts of the gastrointestinal tract (12).

Therefore, a high clinical suspicion with biopsy sampling from all levels of the gastrointestinal tract is required to make a proper diagnosis. Differential diagnosis of eosinophilic gastroenteritis is listed in table 1.

The involvement of different layers of the intestinal walls including mucosal, muscular, or serosal layers leads to different clinical manifestation. Although eosinophilic gastroenteritis can involve any part of the gastrointestinal tract, the stomach and duodenum are the most common sites of involvement (13) and the colon is rarely involved (14,15). Patients present a variety of non-specific symptoms, which can lead to a delay in the diagnosis. It may or may not be accompanied by peripheral eosinophilia. The exact incidence of the disease is unknown because many cases are not properly diagnosed or reported (16). Studies have been suggested that eosinophils may promote IgA class switching by providing active transforming growth factor- β (TGF- β) (17). Since eosinophils in the gut-associated lymphoid tissues (GALT) have an important role in the differentiation of IgM + B cells to IgA + B cells (8), eosinophilic infiltration in the gastrointestinal tract can sometimes be accompanied by a raised level of IgA.

IL-5 plays a major role in eosinophilic differentiation and inhibits their apoptosis in the tissues (18), therefore its excessive production causes eosinophilia, it can also raise serum level of IgA, therefore, increased serum level of IgA can be preceded by both IL5 excessive secretion and peripheral eosinophilia (19).

Since the numbers of blood eosinophil do not necessarily indicate the extent of eosinophil involvement in affected tissues, peripheral eosinophil count is not a reliable observational index to estimate disease activity (20).

Patients with mucosal involvement present with

abdominal pain, nausea, vomiting, diarrhea, blood loss in stool, iron-deficiency anemia, malabsorption, protein-losing enteropathy, and weight loss. Patients with muscular involvement may have gastrointestinal obstructive symptoms. The eosinophilic infiltration of the deep layers of the GI tract usually leads to eosinophilic ascites (21).

In motivated patients who are symptomatic or have evidence of malabsorption, diet therapy with an empiric elimination diet (e.g., a six-food elimination diet including milk, soy, wheat, egg, peanuts/tree nuts, and fish/shellfish) is suggested (22).

In patients who decline a dietary approach or whose symptoms do not improve after diet therapy for six weeks, a trial of prednisone (20 to 40 mg/day) is suggested. Improvement usually occurs within two weeks regardless of the depths of involvement. Prednisone should then be tapered rapidly over the next two weeks. However, some patients require prolonged treatment (up to several months) for the resolution of symptoms (23).

Several other approaches have been described in case reports to treat recurrent or refractory symptoms. However, none of these agents can be recommended for routine treatments due to the limited available data. Ketotifen, sodium cromolyn, montelukast, macrolides, and omalizumab can be used as adjuncts to steroid treatment. Immunomodulators and TNF inhibitors can also be used as steroid-sparing agents (23).

Mepolizumab is an IL-5 antibody. It was shown to improve the symptoms of eosinophilic esophagitis (24). However, its efficacy in EGE is unknown. A pilot study in four patients who were given mepolizumab for EGE showed improvement in peripheral and tissue eosinophilia but no improvement in symptoms of EGE (23).

CONCLUSION

In the diagnosis of EGE, several difficulties are encountered in practice including:

- 1) Patients with eosinophilic gastroenteritis present a variety of non-specific symptoms depending on the site of involvement.
- 2) Eosinophilic infiltration can involve any part of the gastrointestinal tract; hence in suspected patients both endoscopy and colonoscopy should be performed in order to examine the tract.
- 3) Eosinophilic infiltration involves variable depths

of gastrointestinal tract; therefore it is necessary to take various biopsy samples from every layer of gastrointestinal tract and laparotomy or laparoscopic full thickness biopsy is suggested in situations that repeated endoscopic biopsies are negative for eosinophilic infiltration but there is high suspicious for eosinophilic gastroenteritis.

Based on other studies, authors suggest that there might be a strong correlation between peripheral eosinophilia and increased serum level of IgA. In suspected patients with peripheral eosinophilia, a raised IgA serum level might help the diagnosis.

Since IL-5 plays a crucial role in the development and differentiation of eosinophil lineage, authors assume that IL-5 antibodies such as mepolizumab can be very helpful in the treatment of patients with EGE. Their efficacies in the treatment of EGE need further studies.

ACKNOWLEDGEMENTS

The authors would like to thank Mrs. Nasrin Shateri and Dr. Majid Niazkar for their supports.

Conflict of Interest:

The authors have no conflict of interest to declare.

Financial Disclosure:

The authors declared that this study has received no financial support.

CONFLICT OF INTEREST

The authors declare no conflict of interests related to this work.

REFERENCES

1. Kaijser R. Allergic disease of the gut from the point of view of the surgeon. *Arch Klin Chir* 1937;188:36-64.
2. Uppal V, Kreiger P, Kutsch E. Eosinophilic Gastroenteritis and Colitis: a Comprehensive Review. *Clin Rev Allergy Immunol* 2016;50:175-88.
3. Liacouras CA, Furuta GT, Hirano I, Atkins D, Attwood SE, Bonis PA, et al. Eosinophilic esophagitis: Updated consensus recommendations for children and adults. *J Allergy Clin Immunol* 2011;128:3-20.
4. Yun MY, Cho YU, Park IS, Choi SK, Kim SJ, Shin SH, et al. Eosinophilic gastroenteritis presenting as small bowel obstruction: A case report and review of the literature. *World J Gastroenterol* 2007;13:1758-60.

5. Talley NJ, Shorter RG, Phillips SF, Zinsmeister AR. Eosinophilic gastroenteritis: a clinicopathological study of patients with disease of the mucosa, muscle layer, and subserosal tissues. *Gut* 1990;31:54-8.
6. Triantafyllidis J, Parasi A, Cherakakis P, Sklavaina M. Eosinophilic gastroenteritis: Current aspects on etiology, pathogenesis, diagnosis and treatment. *Annals of Gastroenterology* 2002;15:106-15.
7. Zuo, L, Rothenberg ME. Gastrointestinal Eosinophilia. *Immunol Allergy Clin North Am* 2007;27:443-55.
8. Berek C. Eosinophils: important players in humoral immunity. *Clin Exp Immunol* 2016;183:57-64.
9. Spergel JM, Book WM, Mays E, Song L, Shah SS, Talley NJ, et al. Variation in Prevalence, Diagnostic Criteria, and Initial Management Options for Eosinophilic Gastrointestinal Diseases in the United States. *J Pediatr Gastroenterol Nutr* 2011;52:300-6.
10. Pascal RR, Gramlich TL, Parker KM, Gansler TS. Geographic variations in eosinophil concentration in normal colonic mucosa. *Mod Pathol* 1997;10:363-5.
11. Conner JR, Kirsch R. The pathology and causes of tissue eosinophilia in the gastrointestinal tract. *Histopathology* 2017;71:177-99.
12. Ingle SB, Hinge Ingle CR. Eosinophilic gastroenteritis: An unusual type of gastroenteritis. *World J Gastroenterol* 2013;19:5061-6.
13. Alexander P, Jacob S, Paul V. Laparoscopy in eosinophilic jejunitis presenting as subacute bowel obstruction: a case report. *Trop Gastroenterol* 2003;24:97-8.
14. Dobbins JW, Sheahan DG, Behar J. Eosinophilic Gastroenteritis With Esophageal Involvement. *Gastroenterology* 1977;72:1312-6.
15. Haberkern CM, Christie DL, Haas JE. Eosinophilic gastroenteritis presenting as ileocolitis. *Gastroenterology* 1978;74:896-9.
16. Zhang M, Li Y. Eosinophilic gastroenteritis: A state-of-the-art review. *J Gastroenterol Hepatol* 2017;32:64-72.
17. Chu VT, Beller A, Rausch S, Strandmark J, Zänker M, Arbach O, et al. Eosinophils promote generation and maintenance of immunoglobulin-A-expressing plasma cells and contribute to gut immune homeostasis. *Immunity* 2014;40:582-93.
18. Bartemes KR, Cooper KM, Drain KL, Kita H. Secretory IgA induces antigen-independent eosinophil survival and cytokine production without inducing effector functions. *J Allergy Clin Immunol* 2005;116:827-35.
19. Takatsu K, Nakajima H. IL-5 and eosinophilia. *Curr Opin Immunol* 2008;20:288-94.
20. Moshari J, Niazkar HR, Shahri MK, Ghorbani M, Darafshi R. Drug-Induced Eosinophilia Secondary To The Cotrimoxazole Administration In Acute Brucellosis. *Asian J Pharm Clin Res* 2018;11:3-4.
21. Rothenberg ME. Eosinophilic gastrointestinal disorders (EGID). *J Allergy Clin Immunol* 2004;113:11-28.
22. Lee CM, Changchien CS, Chen PC, Lin DY, Sheen IS, Wang CS, et al. Eosinophilic Gastroenteritis: 10 Years Experience. *Am J Gastroenterol* 1993;88:70-4.
23. Gupta N, Aggarwal A, Gupta R, Sule S, Wolf DC. The management of eosinophilic gastroenteritis. *Scand J Gastroenterol* 2015;50:1309-14.
24. Stein ML, Collins MH, Villanueva JM, Kushner JP, Putnam PE, Buckmeier BK, et al. Anti-IL-5 (mepolizumab) therapy for eosinophilic esophagitis. *J Allergy Clin Immunol* 2006;118:1312-9.